

# CHALLENGES OF DIFFERENTIAL DIAGNOSIS OF CONGENITAL UTERINE MALFORMATIONS

PhD, Associate Professor *Nataliya Veresnyuk*

Department of Obstetrics, Gynecology and Perinatology, Faculty of Postgraduate Education  
Ukraine, Lviv, Danylo Halytsky Lviv National Medical University

DOI: [https://doi.org/10.31435/rsglobal\\_wos/31082019/6653](https://doi.org/10.31435/rsglobal_wos/31082019/6653)

---

## ARTICLE INFO

**Received:** 20 June 2019

**Accepted:** 13 August 2019

**Published:** 31 August 2019

---

## KEYWORDS

unicornuate uterus,  
pregnancy,  
dysmenorrhea,  
hematometra.

## ABSTRACT

A unicornuate uterus varies from 2.4 to 13% among Müllerian anomalies and most of them have rudimentary (functional) cavity. Patients with rudimentary horns that contain functional endometrium are at the risk of gynecological and obstetric complications such as ectopic pregnancy, hematometra, endometriosis and poor pregnancy outcomes. These reports describe two cases. One of them regards of a successful pregnancy in non-communicating rudimentary horn of unicornuate uterus and postpartum clinical manifestation of it and another one describes adenomyosis in rudimentary horn. In both cases were difficulties of differential diagnosis of uterus anomalies.

---

**Citation:** Nataliya Veresnyuk. (2019) Challenges of Differential Diagnosis of Congenital Uterine Malformations. *International Academy Journal Web of Scholar*. 8(38), Vol.1. doi: 10.31435/rsglobal\_wos/31082019/6653

---

**Copyright:** © 2019 **Nataliya Veresnyuk**. This is an open-access article distributed under the terms of the **Creative Commons Attribution License (CC BY)**. The use, distribution or reproduction in other forums is permitted, provided the original author(s) or licensor are credited and that the original publication in this journal is cited, in accordance with accepted academic practice. No use, distribution or reproduction is permitted which does not comply with these terms.

---

**Introduction.** The prevalence of unicornuate uterus accounts for 2.4 to 13% of all Müllerian anomalies [1]. This kind of uterine malformations is result of the normal development of one Müllerian duct and absent or incomplete development of the contralateral duct. The rudimentary horn with functional endometrium often associated with ectopic pregnancies. It occurs in approximately 1 out of 76,000 pregnancies to 1 per 150,000. The risk of uterine rupture is about 80% occurring by the end of the second trimester [2]. The unicornuate uterus with a non-communicating rudimentary horn may be associated with infertility, endometriosis, hematometra, urinary tract anomalies, abortions, and preterm deliveries [1, 3]. Pregnant women with unicornuate uterus are group of a high-risk of the complications' development [4, 5, 6].

### Case reports and discussion.

#### Case 1

We report a case of a successful pregnancy in non-communicating rudimentary horn of unicornuate uterus and postpartum clinical manifestation of it.

A 32-year-old woman came to our center with a history of severe cyclic secondary dysmenorrhea since 10 months which had now become intolerable. The dysmenorrhea severity by visual analogue scale for pain score was eight. She had been taking non-steroidal anti-inflammatory medications on and off, which were not relieving the pain. Moreover, the patient tried to become pregnant for two years.

She was married for 11 years. Her menstrual cycles were regular. No history of pelvic inflammatory disorder. She had no bowel or bladder complaints. The first time uterine anomaly was diagnosed by two-dimensional (2D) ultrasound seven years ago. It was classified as a uterus bicornis. The patient could not become pregnancy for five years. She had undergone hysterolaparoscopy for evaluation of case of infertility in 2013, where uterus bicornis with decreasing size of right horn was diagnosed (uterus anomaly was not classified correctly) and the coagulation of endometriosis of right ligamentum sacro-uterine was performed. The patient's left tube during the chromosalpingoscopy was

possible unlike the right one. However, no information about rudimentary horn and its communication with the main horn was reported in her surgical record. The pregnancy became two month later. At the first screening ultrasound, the pregnancy was diagnosed in the right horn. No pregnancy complications were reported to 33 weeks. The patient informed that she regularly attended the routine antenatal care provided in her hometown's health unit but she was not said about the risk of a rudimentary horn rupture due to misdiagnosis of uterus anomaly. The patient was transferred to a tertiary referral hospital with the pregnancy-induced hypertension and intrauterine growth restriction – the fetal size and weight were lower considering the gestational age which was 33-34 weeks and uterus anomaly (uterus duplex uni colli). Obstetric ultrasound examinations at the third trimester of her pregnancy showed a normal insertion of the placenta, low amniotic fluid index and breech fetal presentation. On speculum examination normal vagina with a single cervix were seen. A serial growth ultrasound examination performing until 36 weeks and 4 days' gestation confirmed a low baby weight.

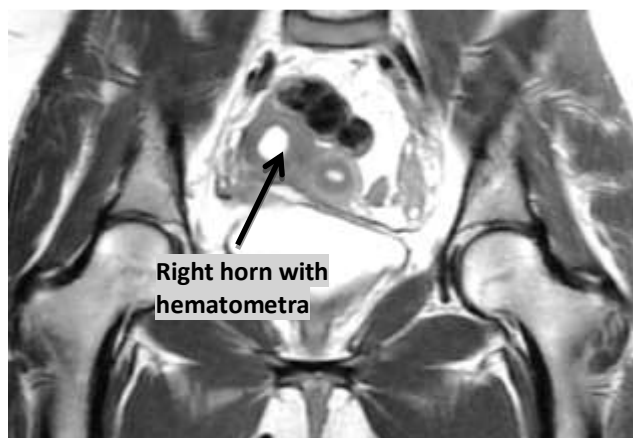At 37 weeks' pregnancy, the patient underwent an urgent cesarean section because of fetal distress and she had a healthy baby girl, with an Apgar score of 6 to 7, weight of 1980g and height of 47cm. During the surgery, unexpectedly no communication with another horn was found. Both her ovaries and tubes were normal. The volume of surgery was limited to caesarean section with drainage of the abdominal cavity.

The mother had hyperthermia during the week after surgery, there were lochia absent from the vagina. Serial ultrasound examinations in the postsurgery period showed decreasing sizes of hematometra in the right rudimentary horn. At day 8 after cesarean section, the patient was discharged home.

After 4 years, the patient came to the Municipal Non-profit Enterprises of Lviv Regional Council «Lviv Regional Center of reproductive health» with complaints of dysmenorrhea and secondary infertility that were described before.

An ultrasound examination, including an baseline (2D) ultrasound assessment of pelvis organs with the following three-dimensional (3D) transvaginal scan of uterus, was performed. The investigation showed a left unicornuate uterus of the dimensions of 44mm × 32mm × 38mm with an normal endometrial thickness. At the right side, a non-communicating rudimentary horn with hematometra of the sizes of 31mm x 15mm and postcesarean scar was described (Class U4a according to the ESHRE/ESGE classification 2013). In addition, hydrosalpinx and endometrioid cyst were diagnosed at the right side. The ultrasonography of kidneys did not detect any deviation. Hysterosalpingography showed the leftside unicornuate uterus with normal passable left tube.

Magnetic resonance imaging without intravenous contrast was performed. The images through the level of the pelvis demonstrated a left sided unicornuate uterus with a single vagina and a single cervix. The right non-communicating horn contained hematometra. Furthermore, small cysts were found in the right ovary (Fig. 1).



*Fig. 1. The MRI imagine shows left unicornuate uterus and right rudimentary horn with hematometra*

Because the presence of a hematometra in the rudimentary horn and severe secondary dysmenorrhea the surgical treatment was indicated. Removal of right rudimentary horn, rightsided salpingectomy and resection of right ovary were performed through laparotomy.

Histological examination showed adenomyosis of the uterine horn, endometrioid cyst of the ovary, hematosalpinx and endometriosis of the removed right fallopian tube. The patient had a good postoperative recovery and she became completely pain-free postoperatively.

### Case 2

A 39-year-old patient was admitted to our clinic with complaints of dysmenorrhea and secondary infertility.

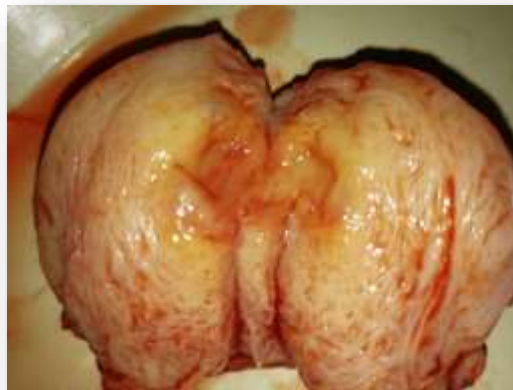
She had a premature labour at 34th week of pregnancy fifteen years ago. Ten years later she started to complain of dysmenorrhea. According to complaints the patient was made ultrasonography where the first time uterus anomaly was diagnosed as a uterus duplex. The patient's karyotype was 46XX. Clinical examination showed normal vagina with a single cervix and the uterus was deviated to the left side.

Differential diagnosis on the 2D ultrasound included uterus bicornis, unicornuate uterus and ectopic pregnancy.

During last year dysmenorrhea became intorelable, so the patient needed to use non-steroidal anti-inflammatory medications and antispasmodic drugs from 6 to 14 days per cycle.

At our clinic, hysterosalpingography demonstrated left-sided hemiuterus with normal tube. Diagnostic hysteroscopy showed a single cervix with a normal cervical canal and a left hemiuterus with an endometrial polyp and a visible left ostium; from the endocervical canal it was not possible to access the right hemiuterus. The endometrial polyp was removed. Than 3D USG transvaginal scan of uterus was performed. It diagnosed unicornuate uterus with right cavitary rudimentary horn with hematometra inside (Class U4aC0V0). On MRI, the diagnosis was confirmed. Therefore, the surgical treatment which included the removal of rudimentary horn was performed (Fig.2).

The pathology report showed adenomyosis of the removed rudimentary uterine horn with dark-colored fluid inside.



*Fig.2. Adenomyosis of the right non-communicating rudimentary horn*

The patient was asymptomatic one month later.

Depending on the subclass, unicornuate uterus may have a different impact on patients' symptoms and reproductive outcomes. However, the real prevalence of the unicornuate uterus is unknown because of many women never complain any symptoms due to the non-functional horn or absent of it. The ESHRE/ESGE classification system helps to divide uterine anomalies into classes and subclasses according to increasing severity of the anatomical deviation and clinical manifestations [7]. Class U4 includes hemi-uterus with the contralateral part incompletely formed or absent. Class U4 is divided into two sub-classes: class U4a or hemi-uterus with a rudimentary (functional) cavity; class U4b or hemi-uterus without a rudimentary (functional) cavity is characterized either by the presence of a non-functional contralateral uterine horn or by aplasia of the contralateral part [7]. 3D ultrasound has been shown to be accurate in the diagnosis of uterine malformations. Our cases were classified as class U4aC0V0, as the patients had a functional cavity, normal cervix and vagina. Unicornuate uterus is often combined with renal anomalies although we did not diagnose any renal pathology in cases which were described [8].

In our first case, the pregnancy became in non-communicating rudimentary horn. According to the literature, it was possible by transperineal migration of sperm or fertilized ovum [1, 9]. Pregnancy in non-communicating rudimentary horn may be associated with serious pregnancy-related complications but this case was an exeption [10]. Only some cases of succesessful pregnancy in the non-communicating rudimentary horn are described. That is why when pregnancy in the rudimentary horn is diagnosed, to prevent a life-threatening uterine rupture, immediate surgery is recommended [1, 2, 9].

Our cases demonstrated difficulties in diagnostic of uterine anomalies. In both women the diagnosis of uterus anomalies were correctly verified only after pregnancy. In these cases the increasing of dysmenorrhea's severity and sizes of hematometra started to progress stubbornly in a few years after labour. Therefore, it seems that the childbirth can be the impetus for the progression of clinical symptoms in patients with a rudimentary (functional) cavity. Surgical resection of a functional rudimentary horn is recommended even if the horn is communicating, whether the woman is pregnant or not [2, 9]. The basic purpose of surgery is pain relief and hence better quality of life what was demonstrated in this case.

#### Conclusions.

1. The diagnosis and the management of the rudimentary uterine horn are often a challenge.
2. It is important to detect unicornuate uterus with rudimentary horn that contains functional endometrium as soon as possible.
3. Patients affected by dysmenorrhea and chronic pelvic pain should always be screened with 2D and 3D ultrasound examinations by highexperienced specialist.
4. The removal of a functional rudimentary horn with or without pregnancy in it is always recommended to prevent menstrual and pregnancy complications.

#### REFERENCES

1. Sánchez-Ferrer ML, Prieto-Sanchez MT, Sánchez Del Campo F. Variations in clinical presentation of unicornuate uterus with non-communicating rudimentary horn (class IIB of the American Fertility Society classification). *Taiwan J Obstet Gynecol*. 2018;57(1):110-114.
2. Blancafort C, Graupera B, Pascual MÀ, Hereter L, Browne JL, Cusidó MT. Diagnosis and laparoscopic management of a rudimentary horn pregnancy: Role of three-dimensional ultrasound. *J Clin Ultrasound*. 2017;45(2):112-115.
3. Tekani H., Karthik G. Unicornuate uterus with a functional non-communicating horn in a Parous Woman. *J Obstet Gynaecol India*. 2016 Dec; 66(Suppl 2): 604-606.
4. Pados G, Tsolakidis D, Athanatos D, Almaloglou K, Nikolaidis N, Tarlatzis B. Reproductive and obstetric outcome after laparoscopic excision of functional, non-communicating broadly attached rudimentary horn: a case series. *Eur J Obstet Gynecol Reprod Biol*. 2014 Nov;182:33-7.
5. Caserta D, Mallozzi M, Meldolesi C, Bianchi P, Moscarini M. Pregnancy in a unicornuate uterus: a case report. *J Med Case Rep*. 2014;8:130.
6. Li X, Ouyang Y, Yi Y, Lin G, Lu G, Gong F. Pregnancy outcomes of women with a congenital unicornuate uterus after IVF-embryo transfer. *Reprod Biomed Online*. 2017; 35(5):583-591.
7. Grimbizis GF, Gordts S, Di Spiezo Sardo A, et al. The ESHRE/ESGE consensus on the classification of female genital tract congenital anomalies. *Hum Reprod*. 2013;28(8):2032–2044.
8. Khati NJ, Frazier AA, Brindle KA. The unicornuate uterus and its variants: clinical presentation, imaging findings, and associated complications. *J Ultrasound Med*. 2012 Feb;31(2):319-31.
9. Li X, Peng P, Liu X, Chen W, Liu J, Yang J, Bian X. The pregnancy outcomes of patients with rudimentary uterine horn: A 30-year experience. *PLoS One*. 2019;14(1): e0210788.
10. Dhar H. Ruptured rudimentary horn at 22 weeks. *Niger Med J*. 2012 Jul-Sep; 53(3): 175–177.