

# CASE REPORT: 17 YEARS SURVIVAL RATE AFTER RADICAL RESECTION OF CEREBELLAR PILOCYTIC ASTROCYTOMA

<sup>1</sup> MD PhD. Valkov Iliya,

<sup>1</sup> MD Ovcharov Mladen,

<sup>2</sup> MD Angelov Dimitar

<sup>1</sup> Neurosurgery Clinic, University Hospital "Dr. G. Stransky" Pleven, Bulgaria

<sup>2</sup> Department of Neuroradiology, University Hospital "Dr. G. Stransky" Pleven, Bulgaria

**Abstract:** A case report is presented to approve 17 years survival after Nafziger- Town operation of a boy, aged 5, 5 years, diagnosed with cerebellar pilocytic astrocytoma. Ventriculo-peritoneal (VP) shunt is applied a week before the radical operation. Pre and postoperative (17 years after) computed tomographic scans (CT) as well as histological verification.

**Keywords:** pilocytic astrocytoma

Abbreviations used: VP- ventriculo peritoneal

CT- computed tomography

GBM- glioblastoma multiforme

**Introduction:** The histological entity pilocytic (juvenile) astrocytoma is believed to be a tumor, rather benign in its biological and clinical behavior. Gross total resection ensures radical cure of the patient.

**Materials and methods:** 5,5 years old boy with a history of 3 months complains of headache, dizziness and vomiting is diagnosed after CT to harbour a cerebellar tumor mass, situated in the midline-right hemisphere, hypodense in its appearance. Cystic volumes are not detected. Compression of the forth ventricle results in rostral hydrocephalus with transependymal resorption. In the course of a week a VP shunt is applied, followed by the radical Nafziger- Town operation when gross total resection of the tumor is achieved.

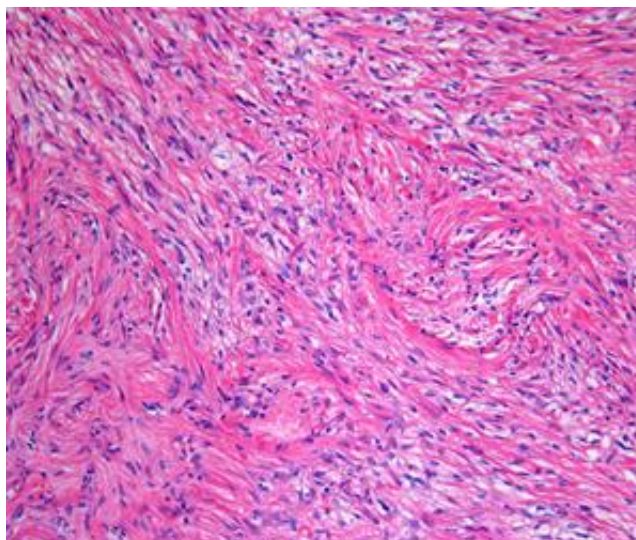
**Results:** Profound clinical getting better is observed immediately after the operation. Postoperative CT scans, including the last one (17 years after) are practically normal. (Shunt is detected normally functioning) The young 21 years old gentleman is University student now. He leads normal life.

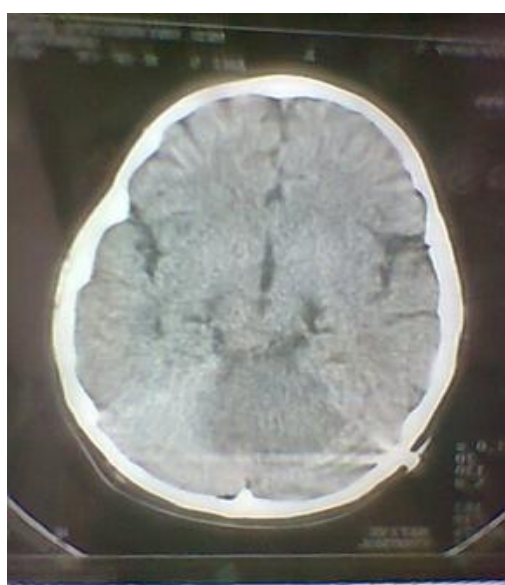

Fig.1. Preoperative CT scan

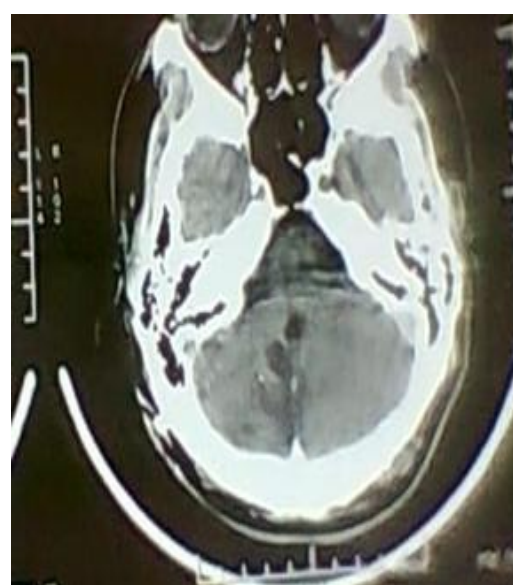

Fig.2. Postoperative result (17 years after)



*Fig.3. Histology: Pilocytic Astrocytoma 20X HE*

**Discussion:** 5 years survival rate after radical operation for pilocytic astrocytoma is reported to be between 75% (1) and 94 %. (2) So operative radicalism should be the goal of a neurosurgeon in order to expect long term survival rate. Nevertheless we have observed malignant transformation of pilocytic astrocytoma to glioblastoma multiforme (GBM), histologically verified, 3 years after the radical resection of the benign tumor. Normal neurological and CT status are observed during this period. Reasons for this are still unknown.

#### REFERENCES

1. Dirven C. M. F., Mooij J. J. A., Molenaar W. M.: Cerebellar pilocytic astrocytoma: a treatment protocol based upon analysis of 73 cases and a review of literature. Child nervous system Volume 13, Issue 1, pp 17-23
2. Wallner KE, Gonzales MF, Edwards MSB, Wara WM, Sheline GE (1988) Treatment results of juvenile pilocytic astrocytoma. Hojer C., Hildebrand G., Lanfermann H., Schroder R., Haupt W.F. (1994): Pilocytic astrocytomas of the posterior fossa: a follow up study in 33 patients. Acta Neurochir 129 129:131
3. Kehler U., Arnolg H., Muller H. (1990): Long-term follow-up of infratentorial pilocytic astrocytomas. Neurocytoma. J Neurosurg 69: 171-176
4. Boch A.-L., Cacciola F., Mokhtari K., Kujas M., Philippon J.: Benign Recurrence of a Cerebellar Pilocytic astrocytoma 45 Years After Gross Total Resection. Acta Neurochirurgica Volume 142, Issue 3, pp 341-346
5. Burkhard Ch., Di Patre P.-L., et al.: A population-based study of the incidence and survival rates in patients with pilocytic astrocytoma. Journal of Neurosurgery June 2003/ vol. 98/ No 6/ Pages 1170-1174